Frontal Lobes: Injury, Assessment and Relevance to Addiction Disorders

OASAS Conference · May 25, 2011

Victor Zelek, Ph.D.

Director of Neuropsychology Service

Northeast Center for Special Care, Lake Katrine, NY

www.northeastcenter.com

The Prefrontal Cortex is to the brain what a…

- CEO is to a corporation
- General is to an army
- Conductor is to an orchestra

Prefrontal Cortex

The prefrontal cortex is the front portion of the frontal lobes and it covers areas forward of the premotor cortex.

Frontal Lobes

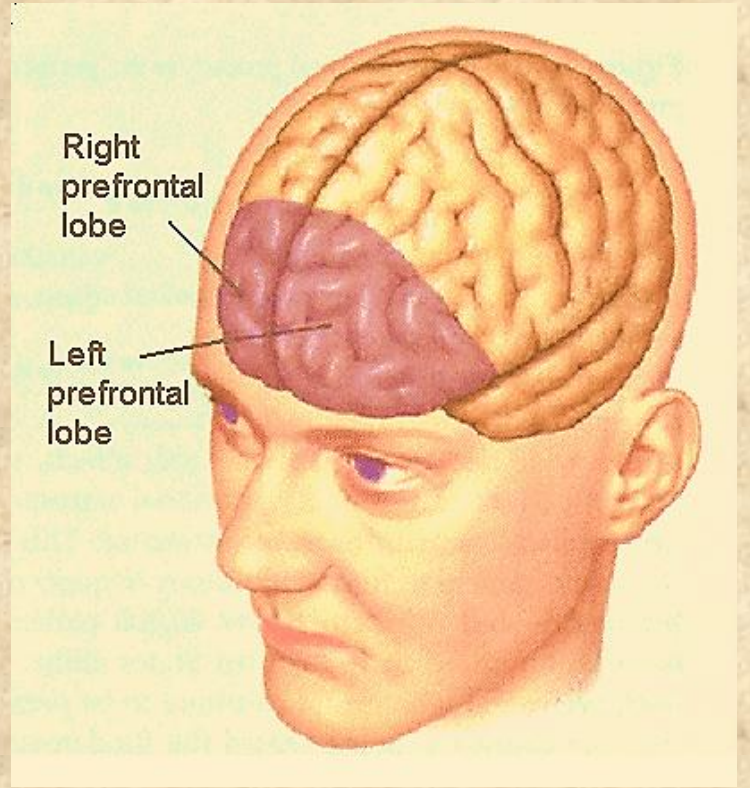

The prefrontal cortex contains a map of the whole cortex.

The prefrontal cortex is 29% of the human brain, 7% of the dog's and 3% of the cat's.

Making Room for the Frontal Lobes

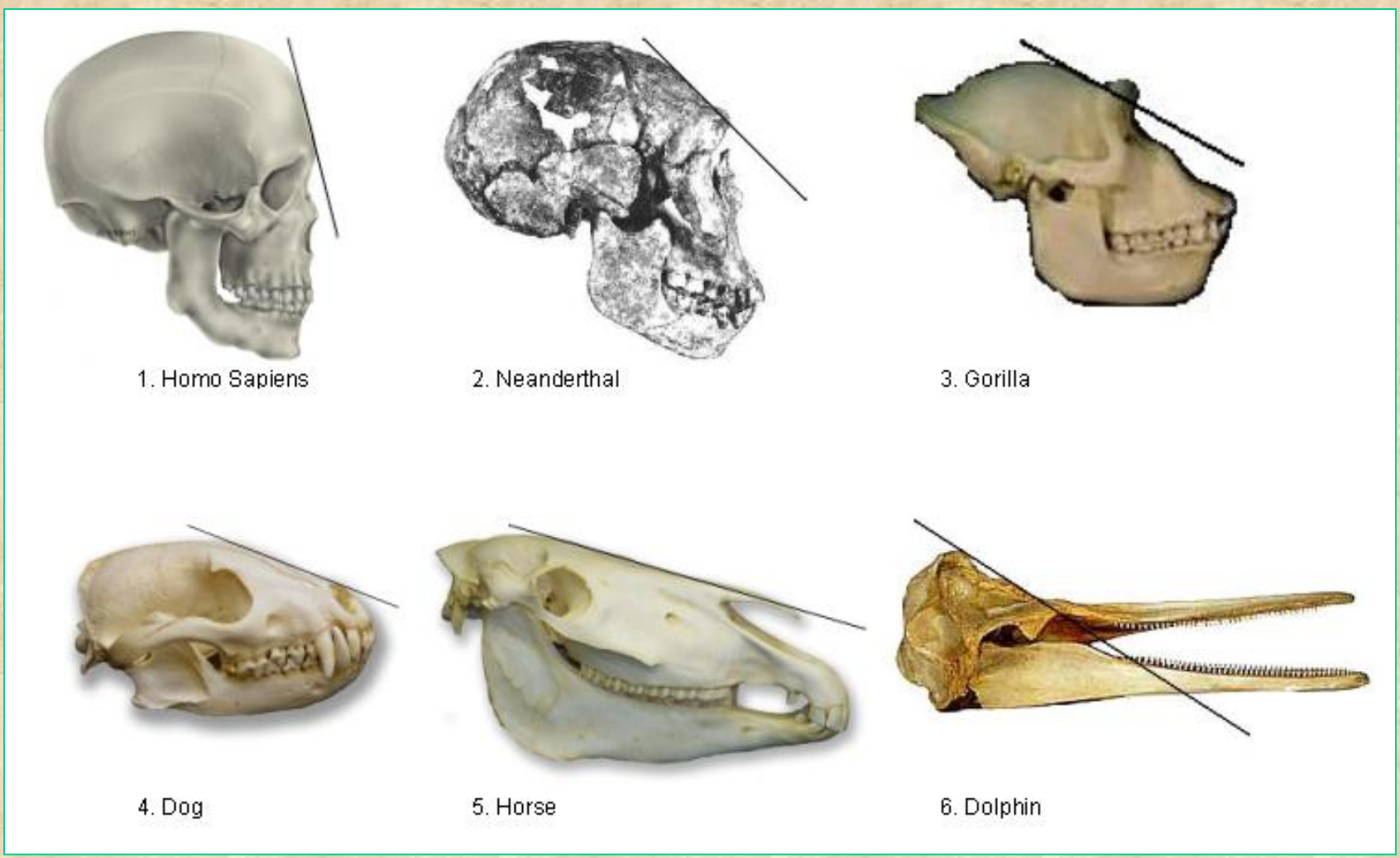

Neuronal and synaptic pruning

Newborns have almost 50% more neurons than mature adults. The process of pruning is especially active in the frontal lobes.

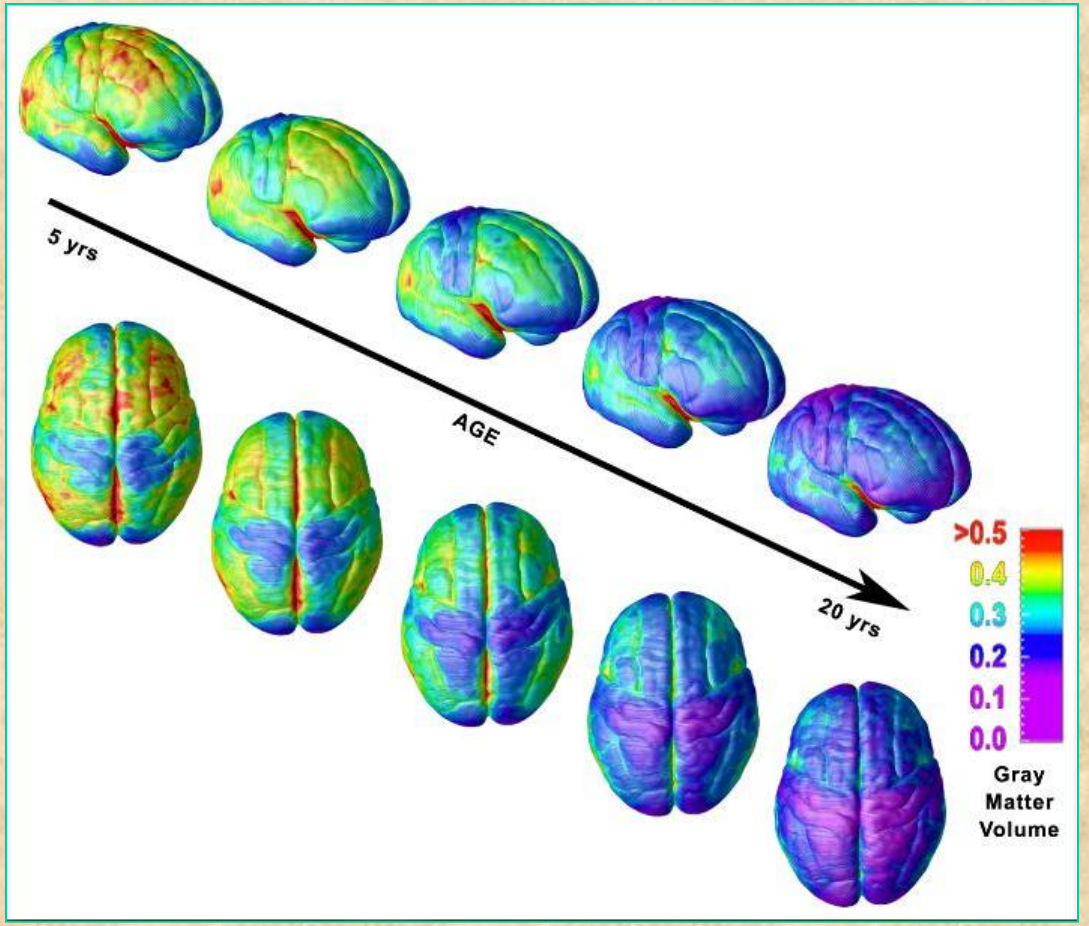

Frontal Lobes

The frontal lobes are involved in “higher” cognitive functions

- Executive functions
- Spontaneity
- Mental effort & goal pursuit
- Working memory
- Foresight & planning
- Sequencing
- Motivation & will
- Judgment
- Impulse control
- Sustained attention
- Supervisory attentional system
- Metacognition
- Complex social behavior
- Emotional regulation
- Understanding humor & metaphors
- Awareness of others

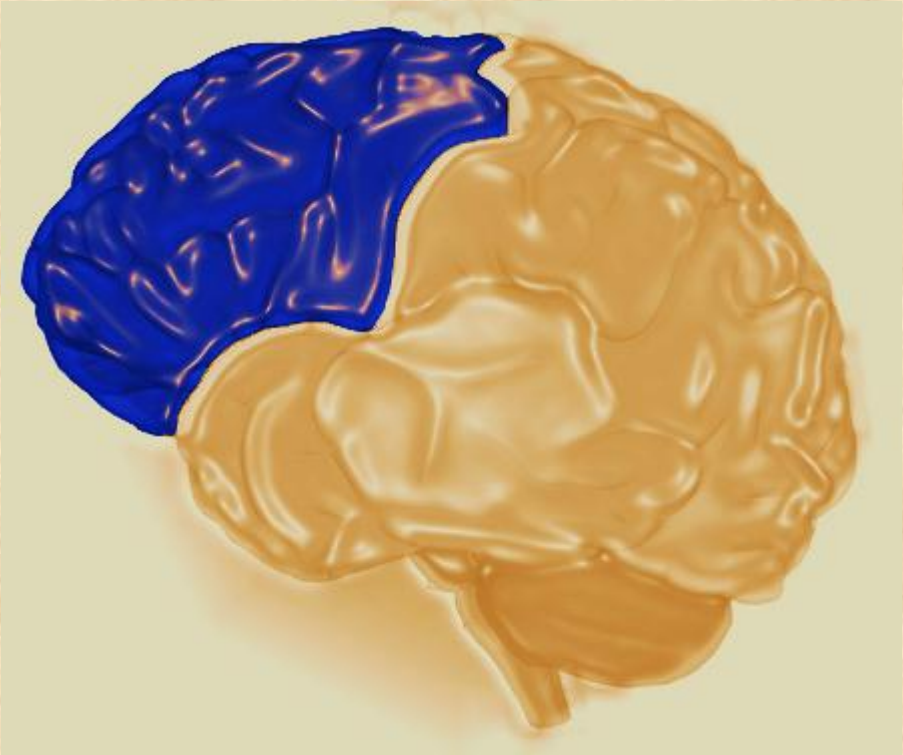

Uneasy Relationship

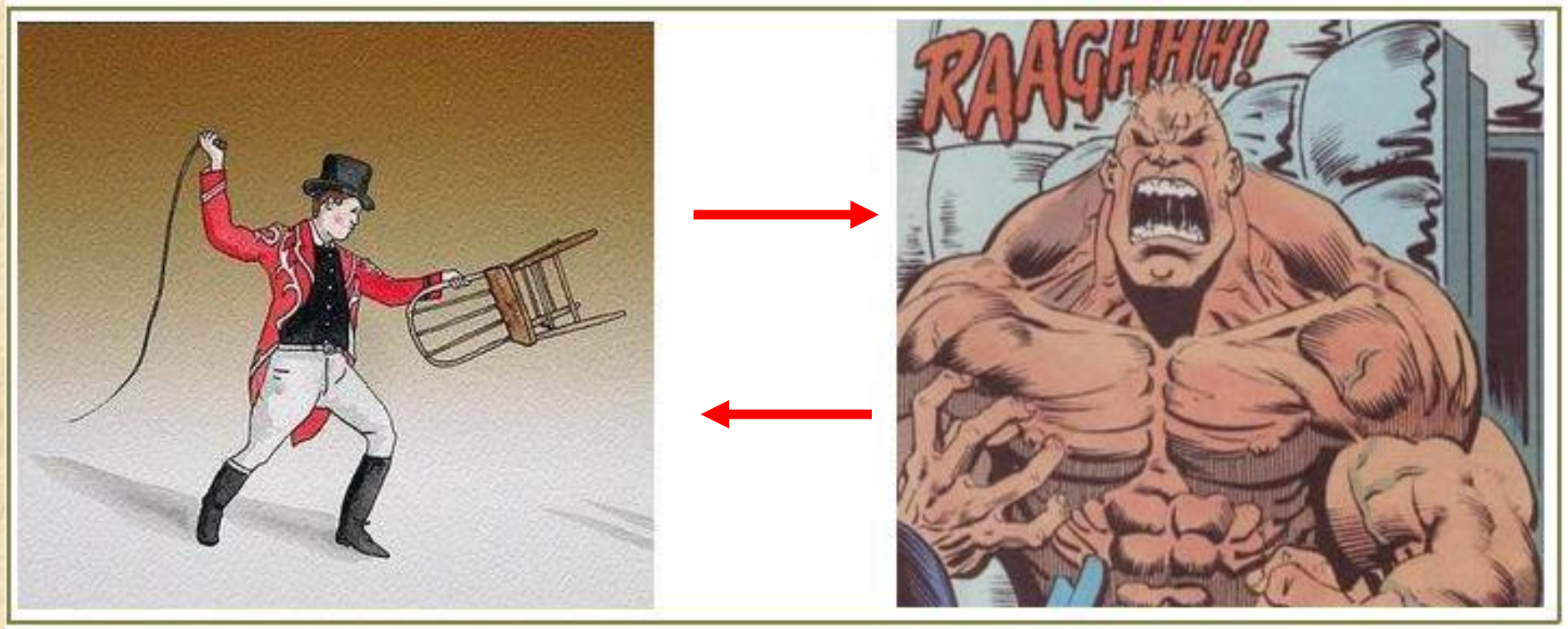

PREFRONTAL CORTEX
(Inhibitory function)

LIMBIC SYSTEM
(Excitatory function)

Nucleus Accumbens

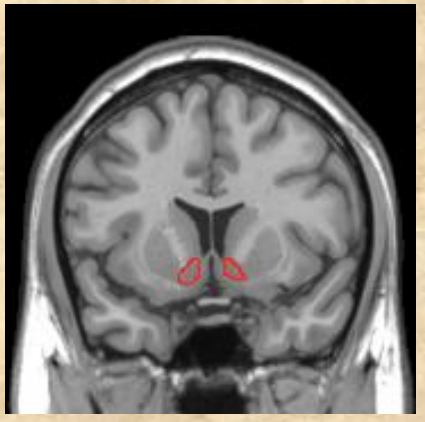

When addicts think about a drug, take a drug, or crave a drug their ***nucleus accumbens*** shows abnormal activation in functional brain imaging studies.

The activity of ***nucleus accumbens*** is moderated by the prefrontal cortex.

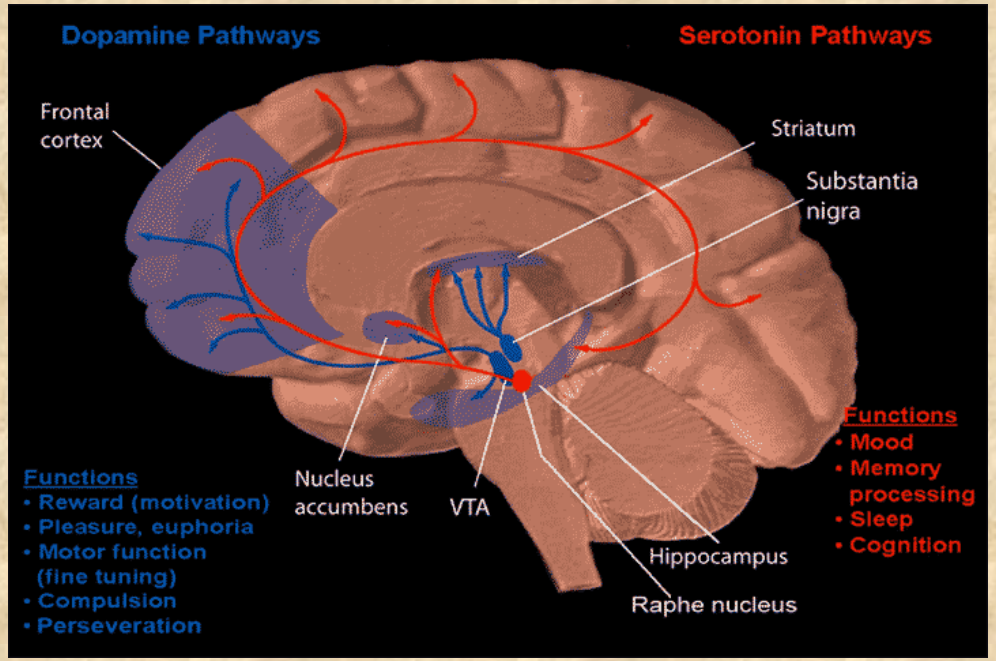

Cortical Connections

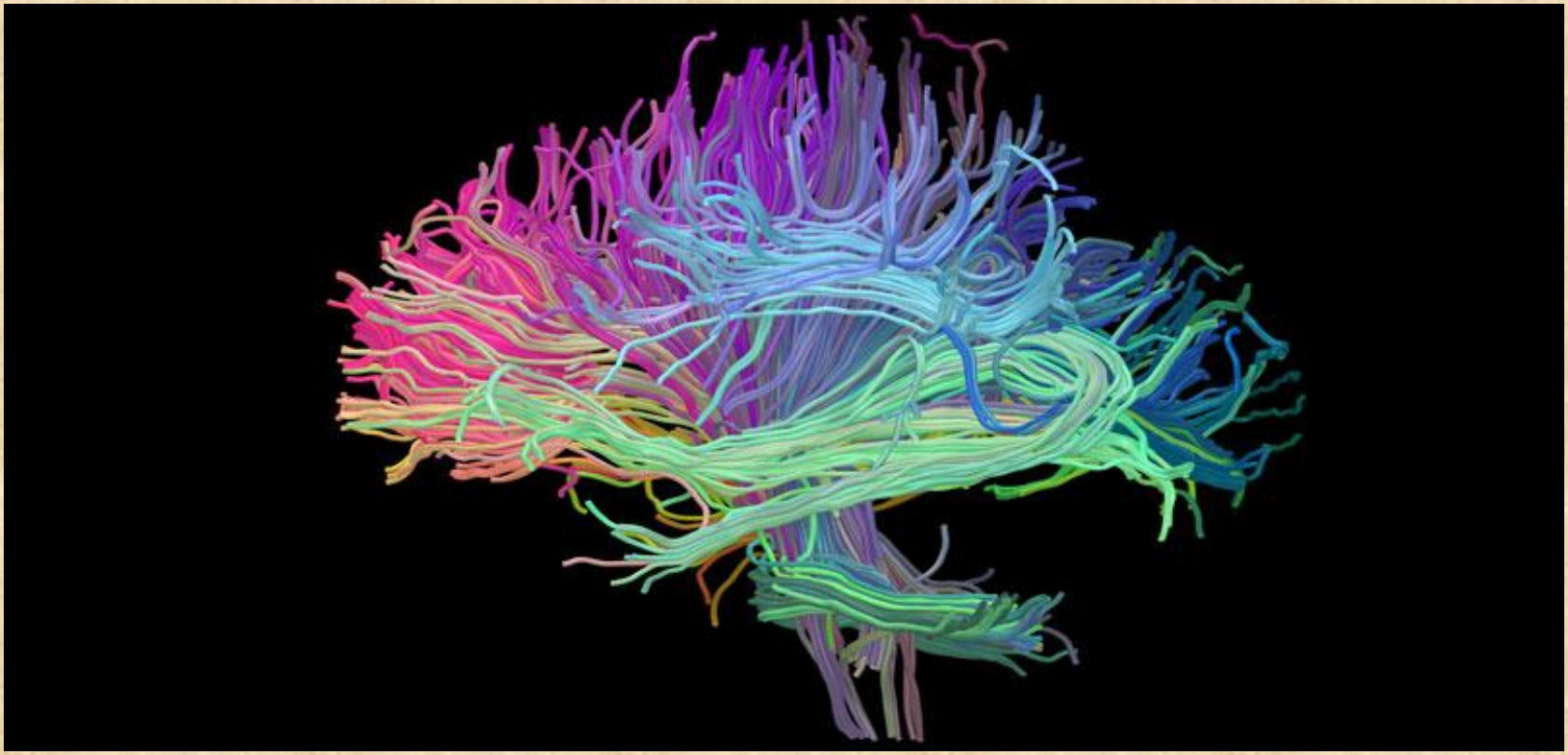

Brain connections visualized using ***diffusion tensor tractography***. Red fiber tracts show ipsilateral connections. Teal color fibers show connections between the two hemispheres traveling across the *corpus callosum*.

Interior Skull Surface

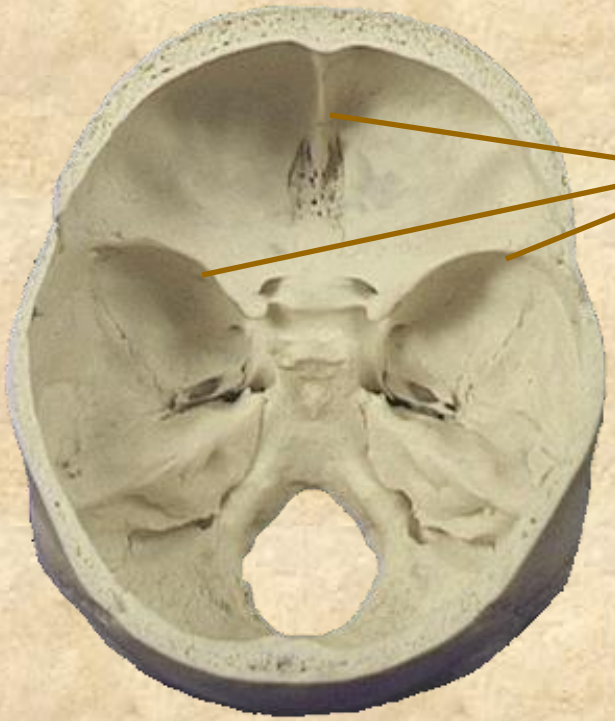

Bony ridges

The base of the skull is rough, with many sharp edges and protuberances.

These ridges can cause injury to the frontal and temporal lobes of the brain during rapid acceleration.

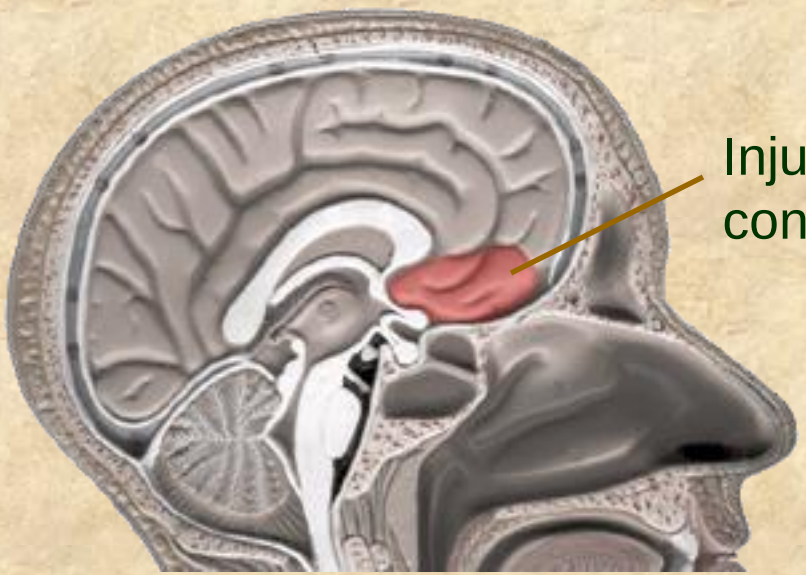

Injury from contact with skull

Phineas Gage

This 19th century railroad worker lost a large chunk of his forebrain when a steel rod was blown through his skull.

He underwent a dramatic personality change – from “purposeful and industrious worker” into a “drunken drifter.”

This classic case of Frontal Lobe injury spurred interest in what was used to be called the Silent Lobes.

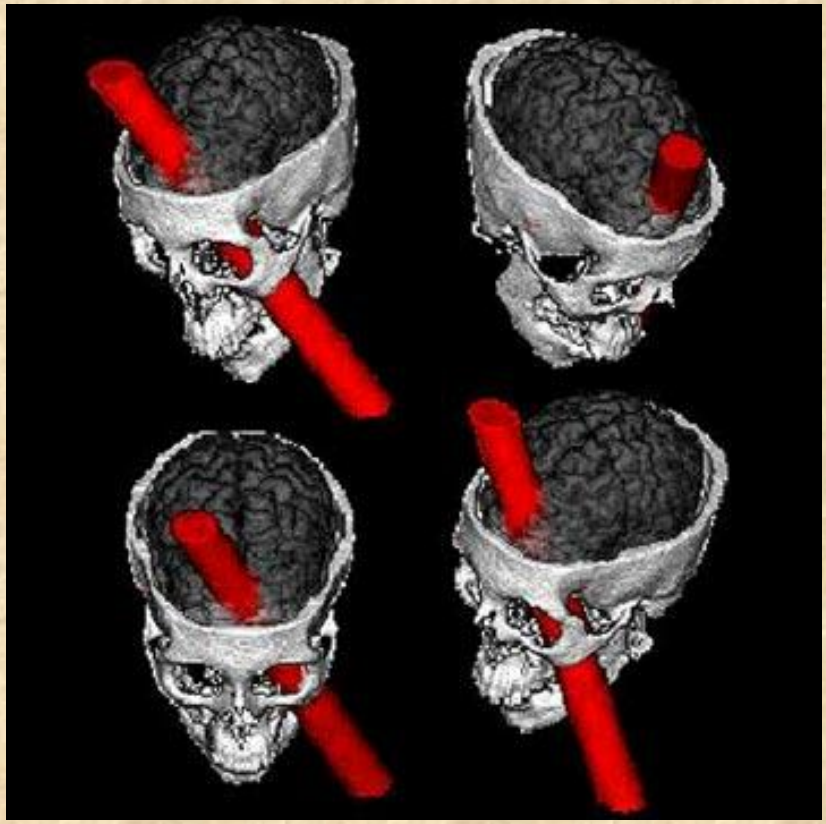

Frontal Lobes

Injury to the frontal cortex leads to

- Impulsivity
- Disinhibition
- Apathy, lack of motivation
- Attention problems
- Difficulty planning
- Disorder of sequencing
- Perseverative behavior
- Difficulty shifting mental sets
- Poor judgment
- Emotional deregulation
- Problems with short-term memory
- Decreased will, drive & energy
- Diminished creativity
- Diminished understanding of humor
- Lack of social sensitivity
- Lack of foresight, but not necessarily insight

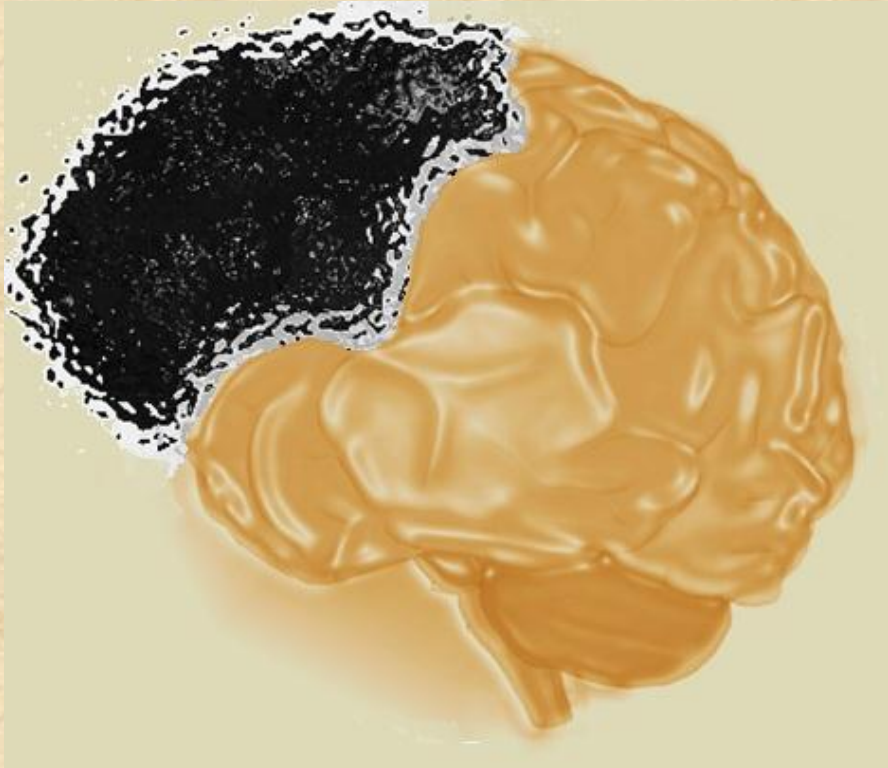

Diffuse Axonal Injury

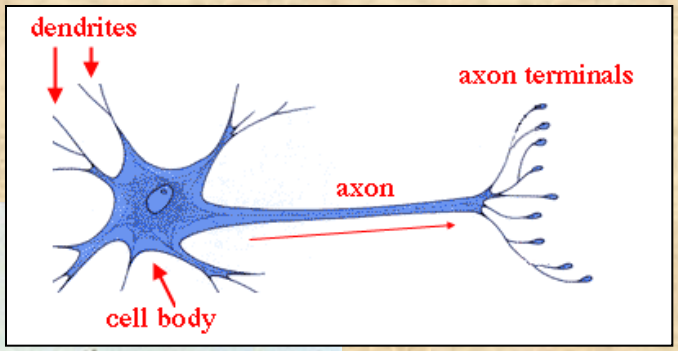

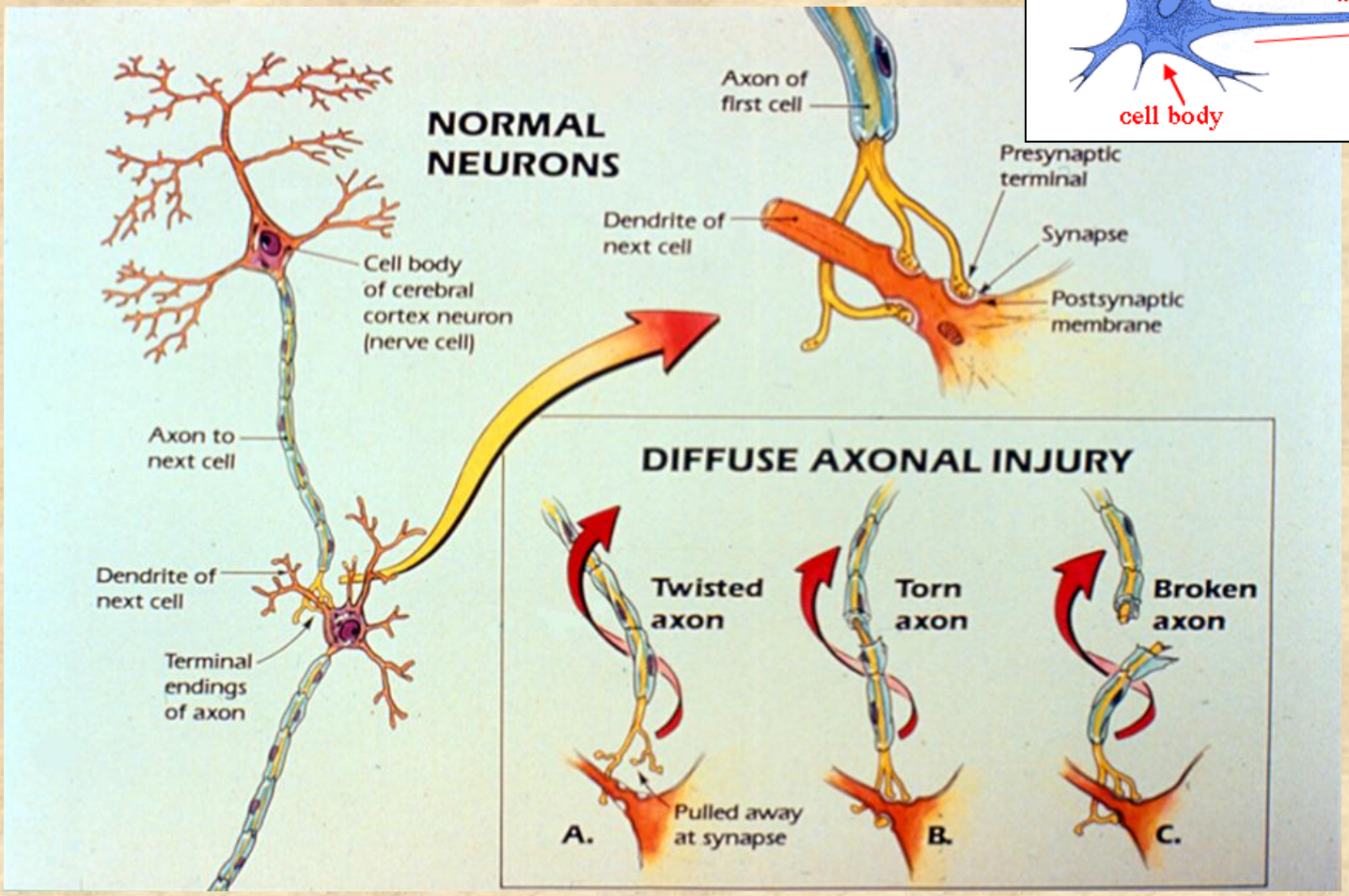

- Regular CT or MRI scans are not sensitive enough to pick up this pathology.
- High Resolution (2-3 Tesla) MRI, Diffusion-Tensor Imaging, Gradient Echo MRI, Tractography or MEG are more sensitive, BUT more expensive and less available.

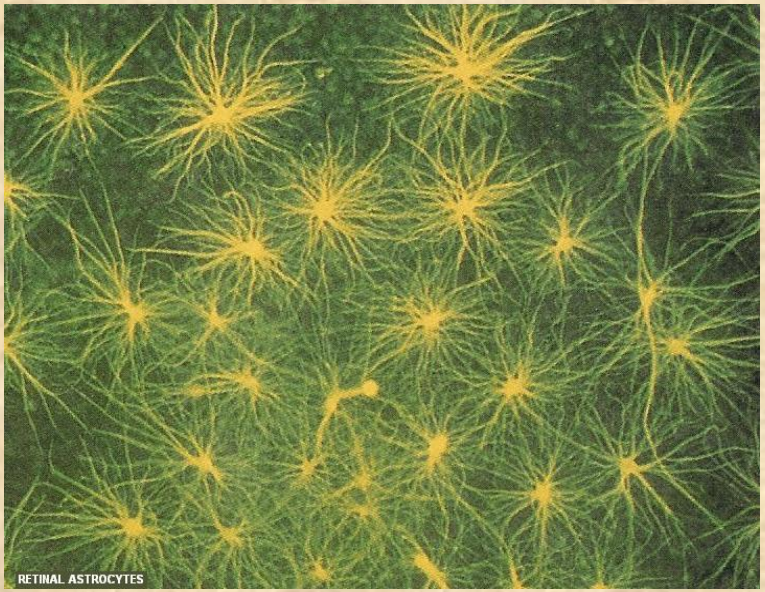
RETINAL ASTROCYTES

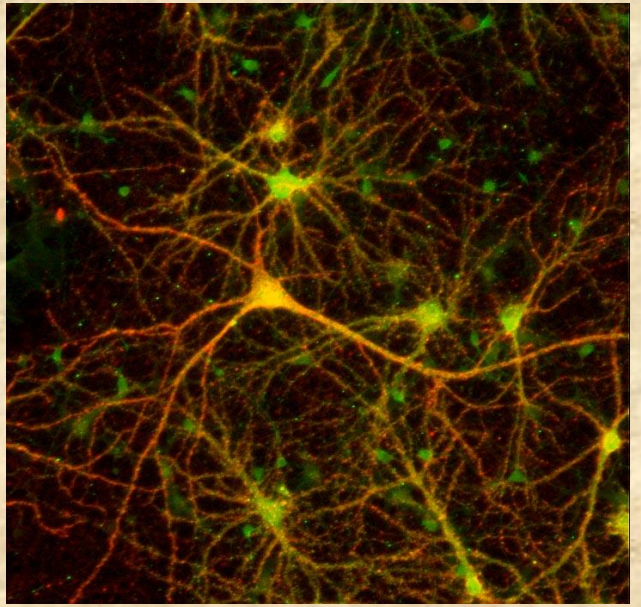

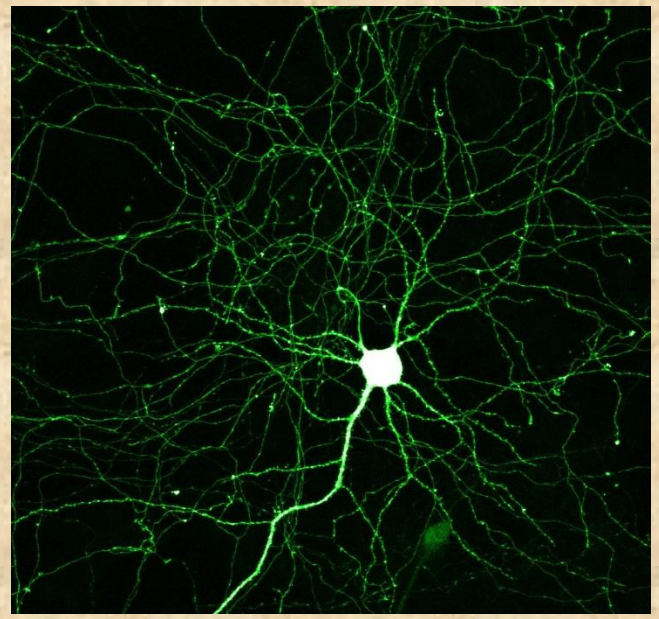

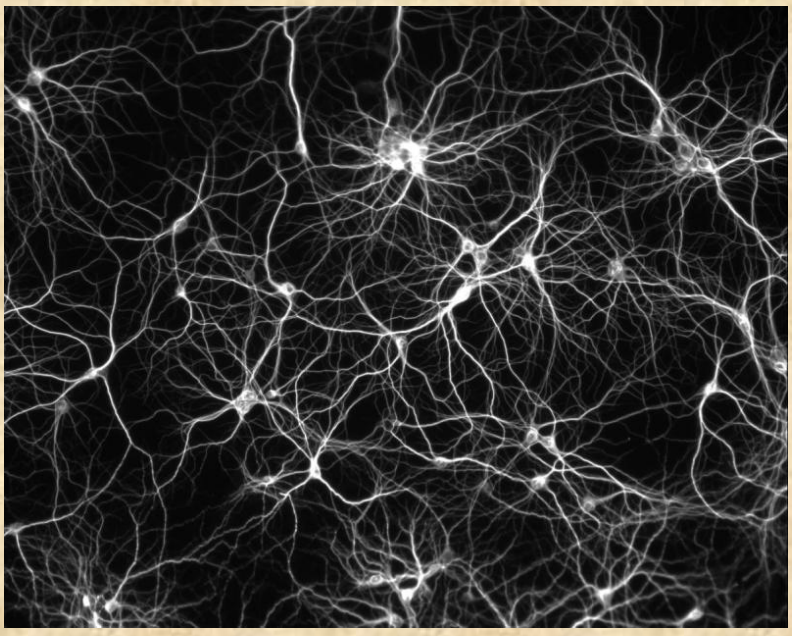

Causes of brain injury

- Traumatic
- Vascular
- Anoxic
- Toxic/metabolic
- Tumors
- Infection
- Iatrogenic

The frontal lobes have an exceptionally low functional breakdown threshold.

"Frontal lobe dysfunction is to the brain disease what fever is to infection – both highly predictable and nonspecific." *–E.G.*

Effects of Extensive Alcohol Abuse on Brain Morphology, Brain Perfusion and Brain Metabolism

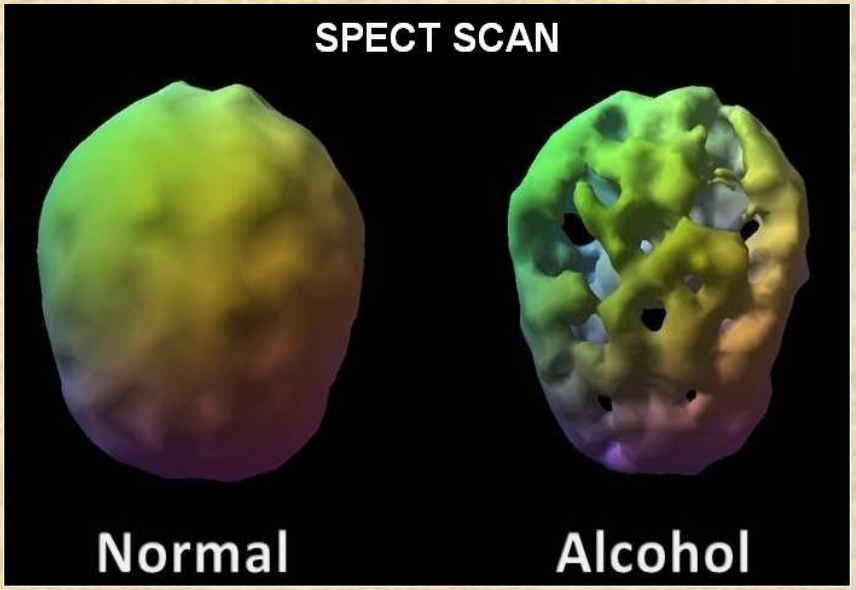

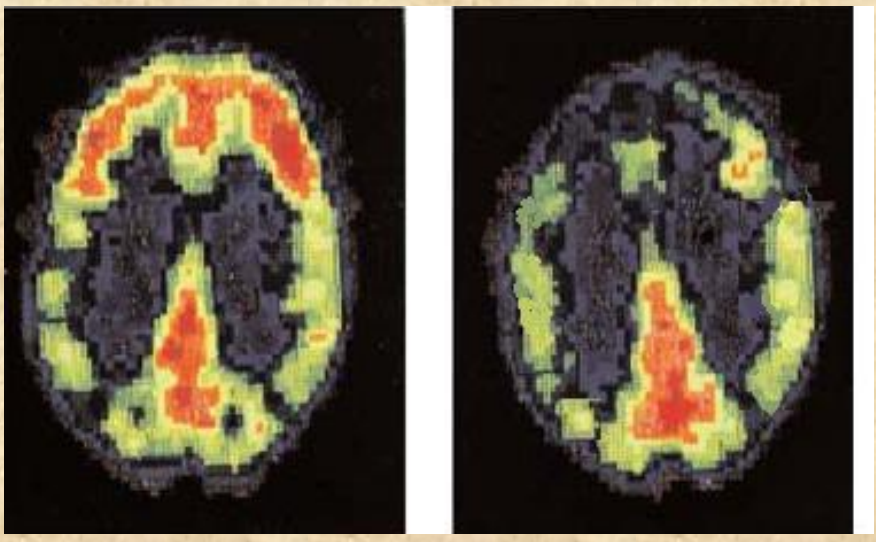

Brain changes in chronic alcoholics

- PET studies show significantly reduced glucose metabolism in the frontal lobes.
- SPECT studies show significant hypoperfusion in the frontal lobes (by 65%).
- MRI studies show volume reduction and cortical atrophy in the frontal lobes, ventricular enlargement and widening of cerebral sulci.
- QEEG studies show reduced brainwave amplitudes in the frontal lobes, increased activity in the limbic structures and in the anterior cingulate, problems with brainwave coherence, symmetry and phase.
- Post-mortem studies show reduced overall brain weight, marked cortical atrophy, and reduction of number of cortical neurons in the frontal lobes.

QEEG

59-year-old man with a history of extensive alcohol abuse and an early onset of Alzheimer's disease. Blue color indicates brainwave activity diminished more than 2 *Std Dev* below the mean.

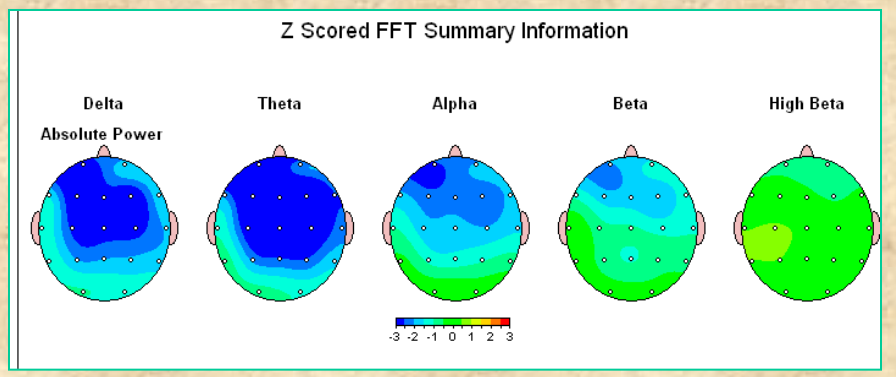

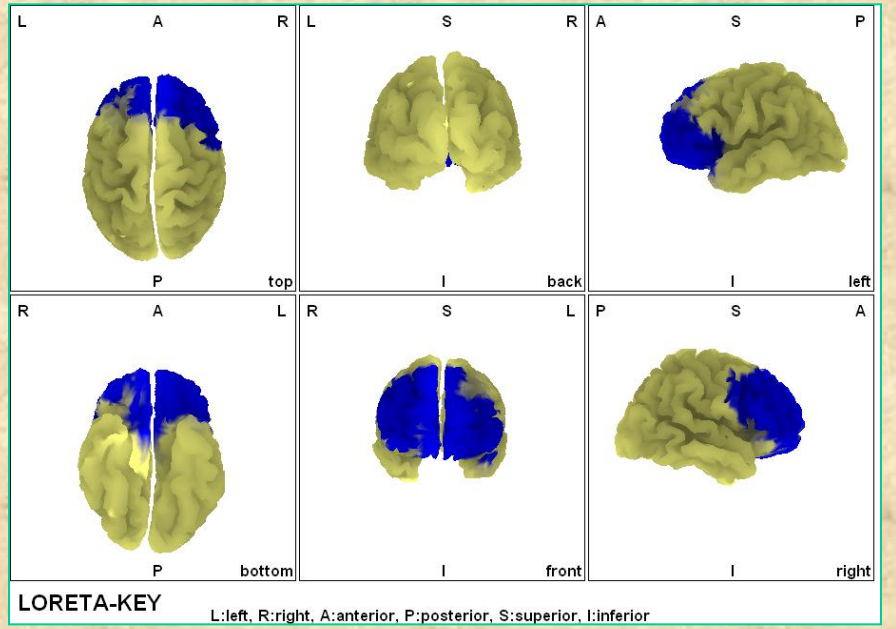

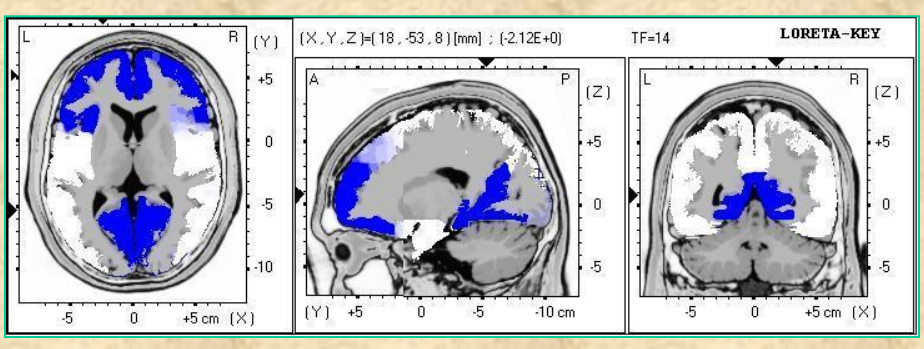

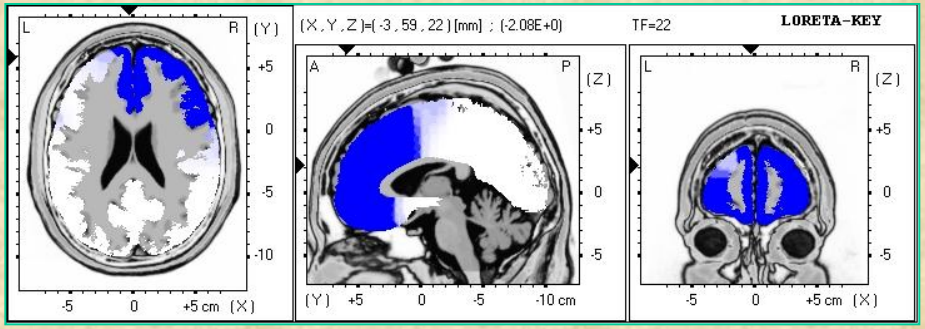

QEEG

20-year-old college student with ADD – before and after smoking marijuana

D.H., 20 y.o., no medication **Dgn: ADD**

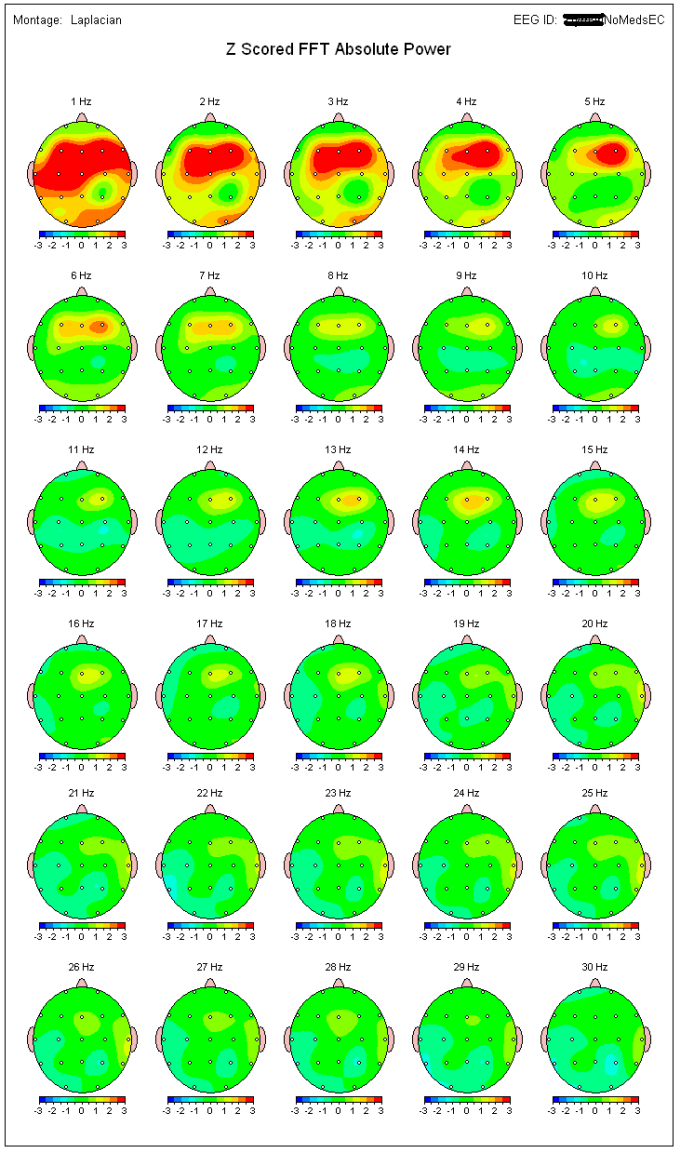

ADD, 2 hours after smoking marijuana

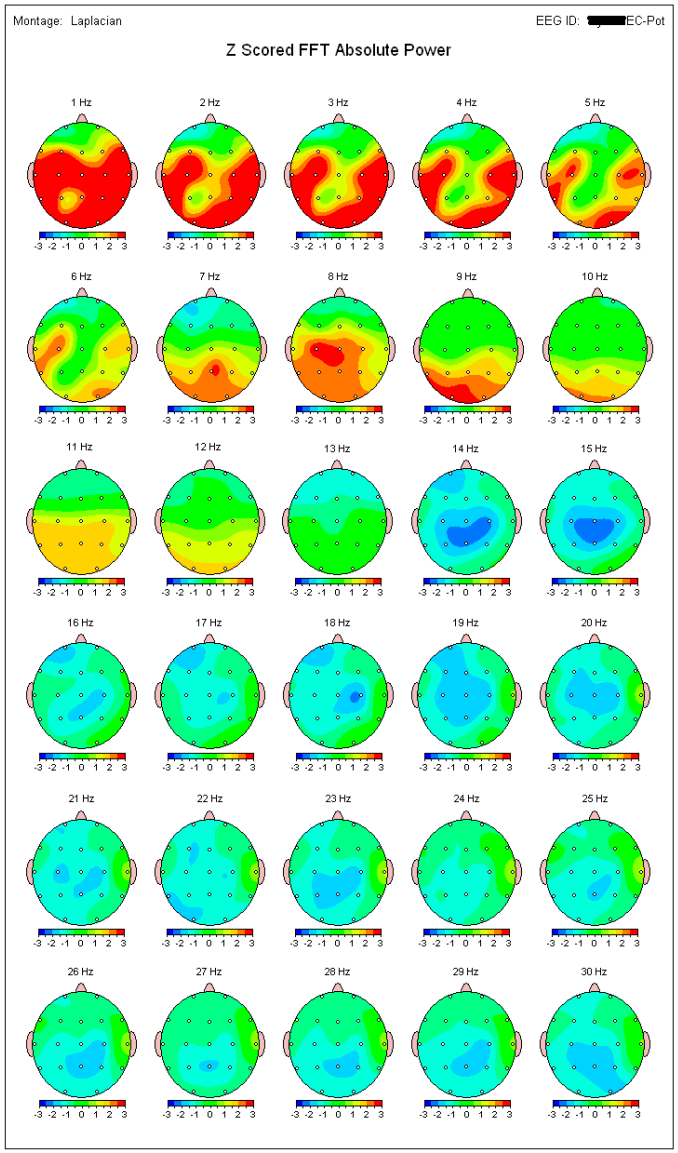

QEEG

40-year-old man with cocaine addiction and severe depression.

O.B., 48 y.o. **Depression, cocaine addiction**

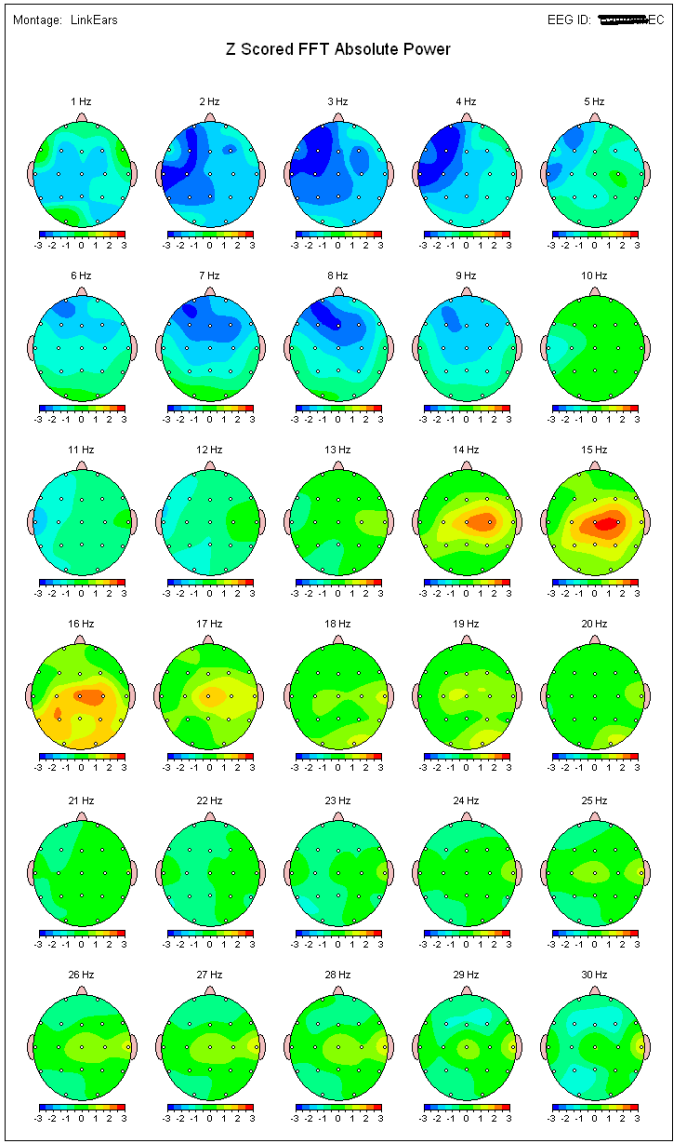

LORETA at the 3 Hz frequency

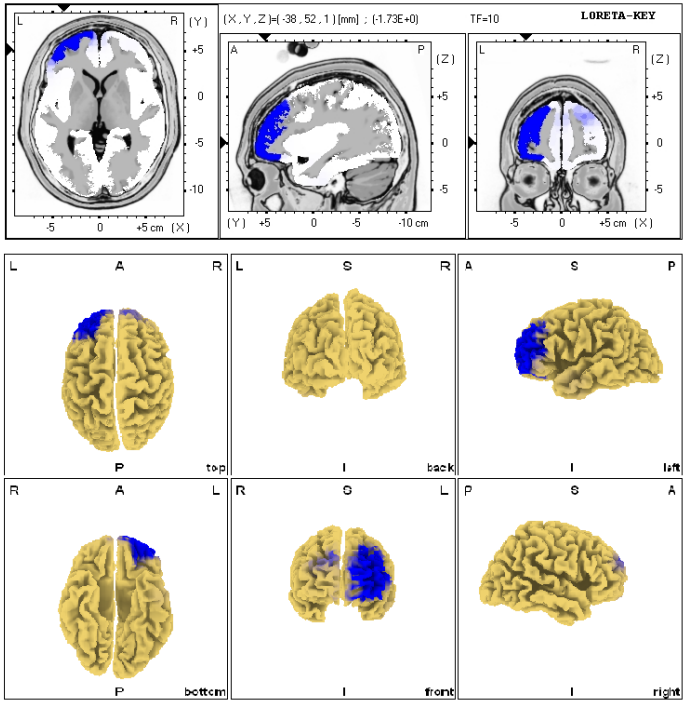

LORETA at the 15 Hz frequency

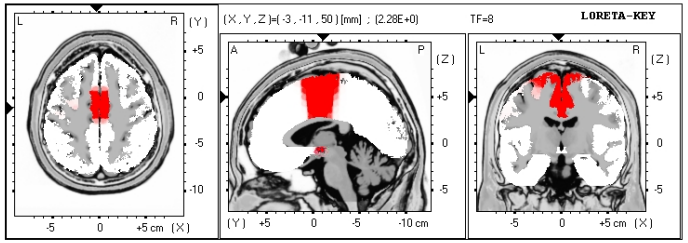

Neuropsychological Tests for Frontal Lobe Dysfunction

- Wisconsin Card Sorting Test
- Stroop Test
- Category Test
- Hayling Sentence Completion Test
- Brixton Spatial Anticipation Test
- Tower of London , Tower of Hanoi Tests
- Trailmaking Test A & B
- Verbal Fluency Test
- Design Fluency Test
- The Proverb Test
- Similarities Test
- Iowa Gambling Test

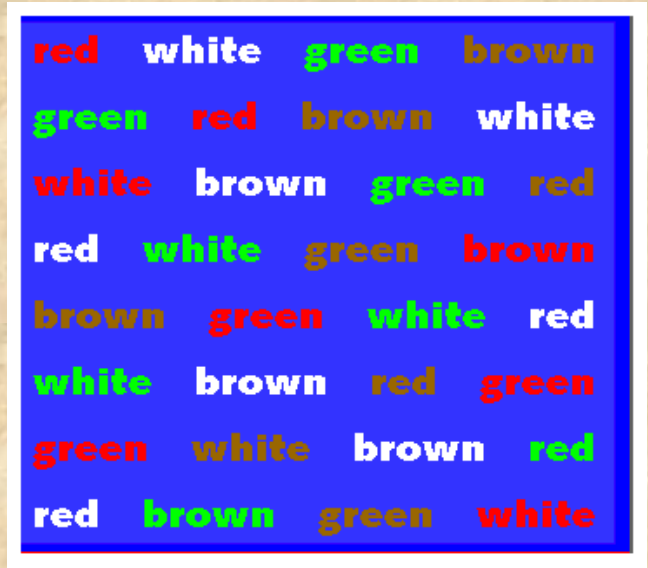



Frontal Lobe Deregulation Syndromes

- Dorsolateral Syndrome, a.k.a. “Pseudodepression”
  (apathy, abulia, lack of drive and initiation, perseveration, rigid thinking)

- Orbitofrontal Syndrome, a.k.a. “Pseudopsychopathic syndrome”
  (disinhibition, impulsivity, recklessness, aggression, jocularity, “tipsy adolescents”)

- Reticulofrontal Disconnection Syndrome
  (ADD-like disorders)

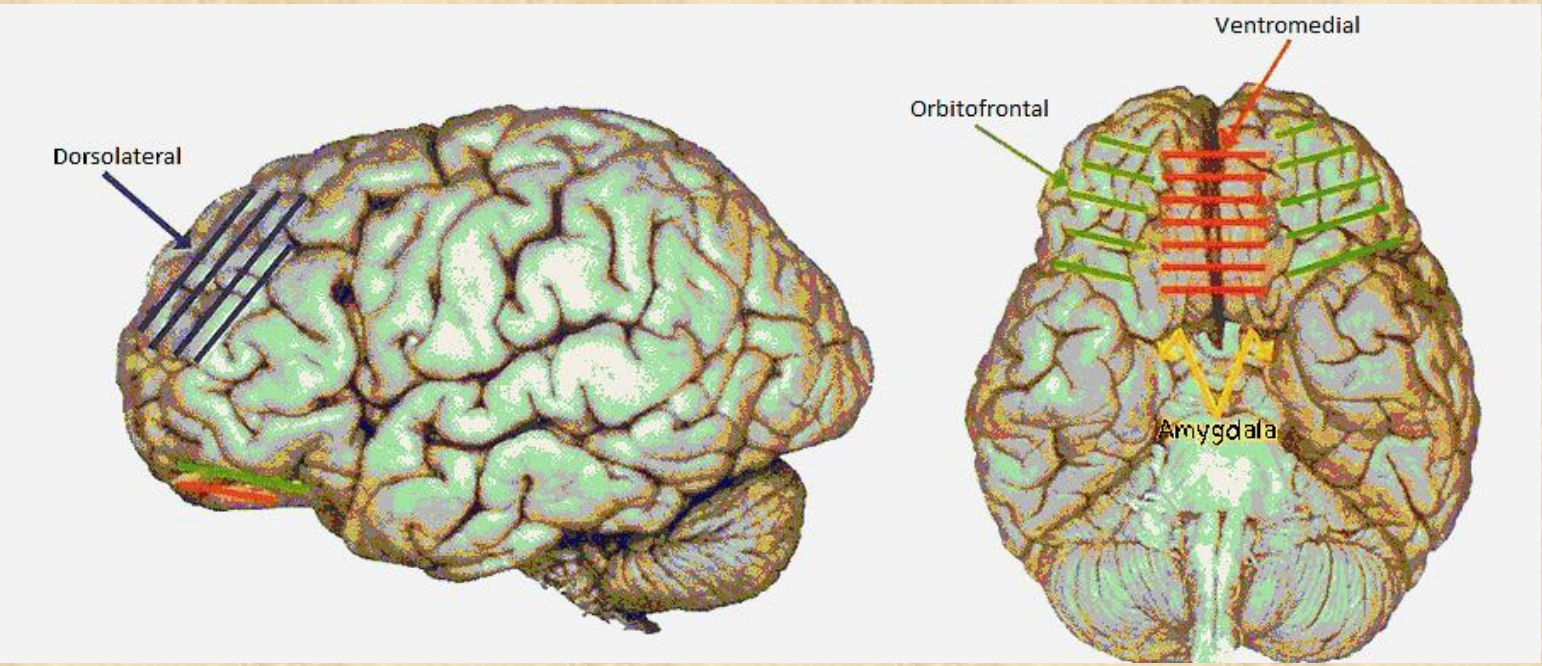



?



Traumatic Brain Injury

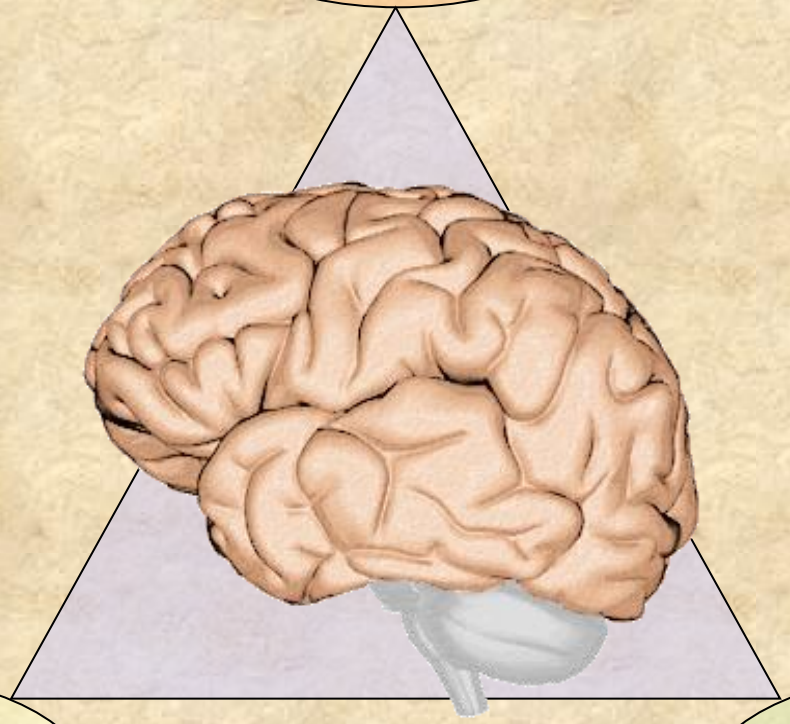

Cognitive/Emotional Problems

Alcohol & Substance Abuse

Vicious Circle

TBI

↓ Processing speed
↓ Mental energy
↓ Organization skills
↓ Impulse control
↓ Judgment
↓ Memory
↓ Inhibition

Lead to

Frustration
Disinhibition
Depression/Anxiety
Lack of foresight
↑ Risk of drug/alcoh abuse

Alcoholism

Compulsive use
↑ Tolerance & use
↓ Impulse control
↓ Judgment
Withdrawal
Failed efforts to control
Increased time using

Lead to

Emotional deregulation
Social isolation
Psychiatric comorbidity
Cognitive impairment
↑ Risk of TBI

Treatment Directions

- **TBI & Alcoholism**
  - Recognition and acceptance
  - Maintaining abstinence
  - Awareness of cognitive deficits
  - Cognotropic drugs
  - Cognitive remediation
  - Emotional self-regulation
  - Psychotherapy, psychoeducation
  - Neurofeedback, Hemoencephalography, LENS

- **Accepting the need for simultaneous treatment**
- **Focusing on the most limiting problem first**
- **Aggressive Case Management**
- **Awareness and interaction of all providers**

The End

Thank you!

(take good care of your frontal lobes!)

Victor Zelek, Ph.D.

Director, Neuropsychology Service

Northeast Center for Special Care, Lake Katrine, NY

www.northeastcenter.com